



UNIVERSITAT DE  
BARCELONA

# Cervical consistency index and quantitative cervical texture analysis by ultrasound to predict spontaneous preterm birth

Núria Baños López

**ADVERTIMENT.** La consulta d'aquesta tesi queda condicionada a l'acceptació de les següents condicions d'ús: La difusió d'aquesta tesi per mitjà del servei TDX ([www.tdx.cat](http://www.tdx.cat)) i a través del Dipòsit Digital de la UB ([diposit.ub.edu](http://diposit.ub.edu)) ha estat autoritzada pels titulars dels drets de propietat intel·lectual únicament per a usos privats emmarcats en activitats d'investigació i docència. No s'autoritza la seva reproducció amb finalitats de lucre ni la seva difusió i posada a disposició des d'un lloc aliè al servei TDX ni al Dipòsit Digital de la UB. No s'autoritza la presentació del seu contingut en una finestra o marc aliè a TDX o al Dipòsit Digital de la UB (framing). Aquesta reserva de drets afecta tant al resum de presentació de la tesi com als seus continguts. En la utilització o cita de parts de la tesi és obligat indicar el nom de la persona autora.

**ADVERTENCIA.** La consulta de esta tesis queda condicionada a la aceptación de las siguientes condiciones de uso: La difusión de esta tesis por medio del servicio TDR ([www.tdx.cat](http://www.tdx.cat)) y a través del Repositorio Digital de la UB ([diposit.ub.edu](http://diposit.ub.edu)) ha sido autorizada por los titulares de los derechos de propiedad intelectual únicamente para usos privados enmarcados en actividades de investigación y docencia. No se autoriza su reproducción con finalidades de lucro ni su difusión y puesta a disposición desde un sitio ajeno al servicio TDR o al Repositorio Digital de la UB. No se autoriza la presentación de su contenido en una ventana o marco ajeno a TDR o al Repositorio Digital de la UB (framing). Esta reserva de derechos afecta tanto al resumen de presentación de la tesis como a sus contenidos. En la utilización o cita de partes de la tesis es obligado indicar el nombre de la persona autora.

**WARNING.** On having consulted this thesis you're accepting the following use conditions: Spreading this thesis by the TDX ([www.tdx.cat](http://www.tdx.cat)) service and by the UB Digital Repository ([diposit.ub.edu](http://diposit.ub.edu)) has been authorized by the titular of the intellectual property rights only for private uses placed in investigation and teaching activities. Reproduction with lucrative aims is not authorized nor its spreading and availability from a site foreign to the TDX service or to the UB Digital Repository. Introducing its content in a window or frame foreign to the TDX service or to the UB Digital Repository is not authorized (framing). Those rights affect to the presentation summary of the thesis as well as to its contents. In the using or citation of parts of the thesis it's obliged to indicate the name of the author.

# Quantitative analysis of cervical texture by ultrasound in mid-pregnancy and association with spontaneous preterm birth

N. BAÑOS<sup>1</sup>, A. PEREZ-MORENO<sup>2</sup>, C. JULIÀ<sup>1</sup>, C. MURILLO-BRAVO<sup>1</sup>, D. CORONADO<sup>2</sup>, E. GRATACOS<sup>1</sup>, J. DEPREST<sup>3</sup> and M. PALACIO<sup>1</sup>

<sup>1</sup>Fetal i+D Fetal Medicine Research Center, BCNatal – Barcelona Center for Maternal-Fetal and Neonatal Medicine (Hospital Clínic and Hospital Sant Joan de Déu), Institut Clínic de Ginecologia, Obstetrícia i Neonatologia, Institut d'Investigacions Biomèdiques August Pi i Sunyer, Universitat de Barcelona, and Center for Biomedical Research on Rare Diseases (CIBER-ER), Barcelona, Spain; <sup>2</sup>Transmural Biotech S. L., Barcelona, Spain; <sup>3</sup>Clinical Department Obstetrics and Gynecology, University Hospitals KU Leuven and Academic Department Development and Regeneration, Biomedical Sciences, KU Leuven, Leuven, Belgium

**KEYWORDS:** image biomarker; quantitative ultrasound; spontaneous preterm birth; texture analysis; uterine cervix

## ABSTRACT

**Objective** New tools are required to improve the identification of women who are at increased risk for spontaneous preterm birth (sPTB). Quantitative analysis of tissue texture on ultrasound has been used to extract robust features from the ultrasound image to detect subtle changes in its microstructure. This may be applied to the cervix. The aim of this study was to determine if there is an association between quantitative analysis of cervical texture (CTx) on mid-trimester ultrasound and sPTB < 37 + 0 weeks' gestation.

**Methods** This was a single-center nested case–control study of a prospective cohort of 677 consecutive women with singleton pregnancy assessed between 19 + 0 and 24 + 6 weeks' gestation. Women at increased risk for sPTB were included unless they received treatment to prevent sPTB. Women who delivered < 37 + 0 weeks (sPTB) were considered as cases and were matched in a 1:10 ratio with randomly selected contemporary controls who delivered at term. For each woman, one ultrasound image of the cervix was obtained for which quality was assessed, cervical length (CL) measured offline and a region of interest in the midportion of the anterior cervical lip delineated for use in local binary patterns analysis of CTx. A learning algorithm was developed to obtain the combination of CTx features best associated with sPTB based on feature transformation and discriminant analysis regression. The ability of the learning algorithm to predict sPTB was evaluated using a leave-one-out cross-validation technique, which produced a CTx-based score for each participant. Receiver–operating characteristics (ROC)

curves were produced and sensitivity, specificity, and positive and negative likelihood ratios were calculated for the optimal cut-off based on the ROC curve. The results were compared with those obtained for CL. Investigators studying the images were blinded to pregnancy outcome at all times.

**Results** Images from 310 women (27 cases and 283 controls) were of sufficient quality and included in the study. Median CTx-based score was significantly lower in cases compared with controls (−1.01 vs −0.07,  $P \leq 0.0001$ ). CTx-based score maintained its significant association with sPTB after adjusting for possible confounders (history of sPTB, conization or Müllerian malformation, and CL < 25 mm). CTx-based score was a better predictor of sPTB (AUC, 0.77; 95% CI, 0.66–0.87) than was CL (AUC, 0.60; 95% CI, 0.47–0.72) ( $P = 0.03$ ). Median CL was similar for cases and controls (37.7 vs 38.6 mm,  $P = 0.26$ ), although cases were more likely to have CL < 25 mm (18.5% vs 0.4%,  $P < 0.001$ ).

**Conclusion** Quantitative analysis of CTx enables the extraction of information relevant to sPTB from ultrasound images to generate a CTx-based score that is associated independently with sPTB. Copyright © 2017 ISUOG. Published by John Wiley & Sons Ltd.

## INTRODUCTION

Spontaneous preterm birth (sPTB) is an important global health issue<sup>1,2</sup> and the identification of women at risk remains a major challenge in obstetrics. Due to the

Correspondence to: Dr N. Baños, BCNatal, Barcelona Center for Maternal Fetal and Neonatal Medicine Hospital Clínic and Hospital Sant Joan de Déu, Universitat de Barcelona, Sabino de Arana 1, 08028 Barcelona, Spain (e-mail: nbanos@clinic.cat)

Accepted: 5 May 2017

huge health, economic and social impact worldwide<sup>3,4</sup>, an effective screening method is needed. Cervical assessment is a key factor in risk evaluation, as sPTB is a multifactorial syndrome that is preceded commonly by premature cervical ripening<sup>5,6</sup>. As implementation of cervical-length (CL) measurement as a screening method in the general population is still controversial<sup>7–9</sup>, the development of innovative tools to detect premature cervical remodeling is needed in order to improve the identification of women at increased risk of sPTB. Quantitative texture analysis has been used to extract robust features from the ultrasound image of a particular tissue to detect subtle changes in its microstructure<sup>10–12</sup>. The feasibility of analysis of cervical texture (CTx) for quantifying cervical tissue changes throughout pregnancy has been shown previously<sup>13</sup>, confirming the underlying hypothesis that cervical remodeling during a normal pregnancy can be detected on CTx analysis.

The aim of this study was to evaluate the association between quantitative analysis of CTx visualized on mid-trimester ultrasound and sPTB <37+0 weeks.

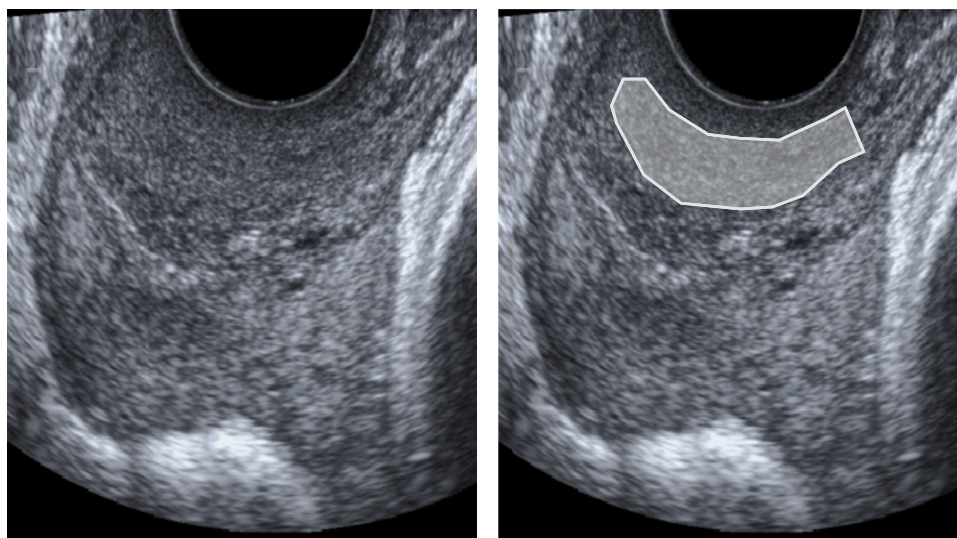
## METHODS

This was a single-center, nested case–control study of a prospective cohort of 677 consecutive women with singleton pregnancy assessed between 19+0 and 24+6 weeks' gestation. Women with a sPTB risk factor (history of sPTB or miscarriage  $\geq 16$  weeks, and cervical intervention or Müllerian malformation) were included unless they received treatment, such as progesterone, cervical cerclage or cervical pessary, to prevent sPTB. Also excluded were those with preterm birth for fetal or maternal indication, including induction of labor (IOL) for preterm prelabor rupture of membranes (PPROM). Data on maternal characteristics, obstetric history and perinatal outcome were collected prospectively.

Gestational age was calculated based on crown–rump length measured on first-trimester ultrasound. The study protocol was approved by the local Ethics Committee of the Hospital Clínic (ID HCB 2014/0089) and Hospital Sant Joan de Déu (ID PIC-147-15), and all pregnant women provided written informed consent.

One image of the uterine cervix was obtained for each woman. Images were acquired by experienced sonographers who were accustomed to performing screening ultrasound in the study center. An image-acquisition guide<sup>13</sup> was followed by the sonographers in order to ensure that the requirements for further analysis of the images were met.

A sagittal view was obtained of the cervix occupying two-thirds of the screen, without exerting any pressure with the transducer, so that the diameters of the anterior and posterior cervical lips were similar (Figure 1). The internal and external os, as well as the cervical canal, were identified and the entire cervical structure visualized, avoiding zooming and using only the depth function. The focus was placed on the middle of the anterior cervical lip. The cervix was angled horizontally on the image. Shadows and saturations were avoided if possible. Any post-processing functions, such as speckle reduction imaging or smoothing, were inactive. No online measurements were made. Gain and harmonics were at the discretion of the physician. Images were acquired with Siemens Sonoline Antares (Siemens Medical Systems, Malvern, PA, USA) or Voluson 780 Pro, Voluson S6, Voluson E6 or Voluson E8 (GE Medical Systems, Zipf, Austria) ultrasound machines, with a 2–10-MHz vaginal probe. Data were collected digitally in the original Digital Imaging and Communication in Medicine (DICOM) format and stored for offline analysis in a custom-made program with a graphical user interface using MATLAB R2010b (version 7.11.0.584; The Mathworks Inc., Natick, MA, USA).



**Figure 1** Sagittal view of cervix with region of interest (largest homogeneous region in middle part of anterior cervical lip) for cervical texture analysis delineated.

After reviewing perinatal outcomes, women who delivered after the spontaneous onset of labor at  $< 37 + 0$  weeks (sPTB), regardless of membranes rupture, were considered as cases and were matched in a 1:10 ratio with contemporary controls who delivered at term. Controls were selected by random uniform sampling using MATLAB R2010b.

All selected images ( $n = 352$ ) underwent a quality control process (performed by A.P.) before delineation, according to the acquisition criteria to ensure that they were suitable for CTx analysis. To perform quantitative analysis of CTx, a region of interest (ROI) from the ultrasound image was delineated offline manually. The selected ROI was defined as the largest homogeneous region in the middle part of the anterior cervical lip avoiding the cervical canal, the glandular area, and the internal and external cervical or a (Figure 1). The minimum ROI size needed to obtain features using the local binary patterns (LBP) method was 400 pixels. Afterwards, CL was measured offline as the outer to the inner cervical os following established guidelines<sup>14</sup>. CL measurement and ROI delineation were performed by three independent operators (N.B., C.M. and C.J.) who were blinded to pregnancy outcome.

### Learning algorithm based on cervical texture

Ultrasound image feature extraction was based on LBP, namely a multiresolution grayscale and rotation-invariant approach. The LBP texture-based method has been used widely for texture classification in the computer vision field<sup>15,16</sup>. The LBP method computes the distribution of binary patterns in the circular neighborhood of each pixel, which is characterized by the radius ( $r$ ) and number of equally spaced neighboring pixels ( $p$ ). The purpose of applying the LBP method is to characterize microstructural changes of the uterine cervix by characterizing speckle patterns. In our study, uniform patterns were defined by  $p = 16$  and  $r = 1$ , resulting in 18 specific texture features from each ultrasound scan within the ROI, related to 18 different uniform patterns. In order to obtain the combination of these textural features associated best with sPTB, we computed a learning algorithm based on two modules, including feature transformation and then discriminant analysis-regression. Specifically, a principal component analysis was applied to reduce dimensionality of features into a limited number of linear feature combinations, thus obtaining the most relevant features that explained 95% of the variance within the observed sample. The discriminant analysis regression of the transformed components was estimated using statistical significance of a multivariate analysis of variance (MANOVA) test, thus providing the most discriminant axis (MDA), defined as the most discriminant combination of the transformed features, which maximized distance between the two groups.

### Statistical analysis

Data distribution was assessed using the Shapiro–Wilk test of normality. Results are described as absolute

and relative frequencies for qualitative variables and as median and interquartile range for quantitative variables. Continuous data were compared using the Mann–Whitney  $U$ -test and categorical variables using the chi-square or Fisher's exact test. The ability of the CTx algorithm to predict sPTB blindly was evaluated using a leave-one-out cross-validation (LOOCV) technique, and thus a CTx-based score from each woman that combined the transformed CTx features was obtained. Box-and-whiskers plots were used to illustrate the differences between cases and controls for CTx-based score and CL. Stepwise multivariate logistic regression analysis was performed to obtain crude (OR) and adjusted (aOR) odds ratios. A significance level of 0.1 was defined to exclude variables from the saturated model. If the potential confounder changed the estimate of risk by 10% or more, it was considered importantly different and was left in the model. CTx-based score aOR from the model including all candidate confounders is also presented. Classification performances of the CTx-based score and CL were computed by inspection of different thresholds within the sample to estimate ROC curves. The resulting areas under the ROC curves (AUCs) were compared using the DeLong method. Sensitivity, specificity and positive (LR+) and negative (LR–) likelihood ratios and their 95% CIs, with regard to predicting sPTB  $< 37 + 0$  gestational weeks, were calculated for the optimal cut-offs based on the ROC curve for CTx-based score and CL, and for CL  $< 25$  mm. The optimal cut-off is the one corresponding to the point on the ROC curve situated farthest from the reference line. A two-sided type-I error rate of 5% was applied throughout statistical testing. All analyses were performed using STATA/IC 13.0 (StataCorp, College Station, TX, USA).

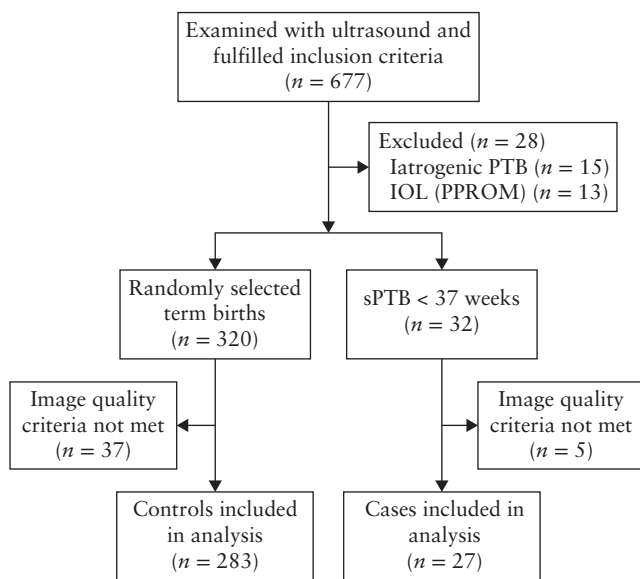
## RESULTS

From March 2015 to March 2016, 677 women were included prospectively in the cohort. After reviewing perinatal outcome, 28 women were excluded (15 iatrogenic PTBs due to fetal or maternal indication, and 13 IOL owing to PPRM). Among the 649 patients who fulfilled the inclusion criteria, there were 32 (4.9%) sPTBs  $< 37 + 0$  weeks. These were matched with 320 randomly selected term births. Based on image quality, five cases and 37 controls were excluded. This left a total of 310 women (27 cases and 283 controls) in the study (Figure 2). Clinical characteristics and maternal and perinatal outcomes are shown in Table 1. There were no differences between cases and controls in baseline demographic characteristics, except for the prevalence of sPTB risk factors (history of sPTB, conization or Müllerian malformation). Median CL was comparable between the groups, but cases were more likely to have CL  $< 25$  mm than controls (18.5% (5/27) vs 0.4% (1/283),  $P < 0.001$ ).

Regarding CTx analysis, three textural features that explained 95% of the variance within the observed sample were selected by principal component analysis. Median CTx-based score was significantly lower in cases.

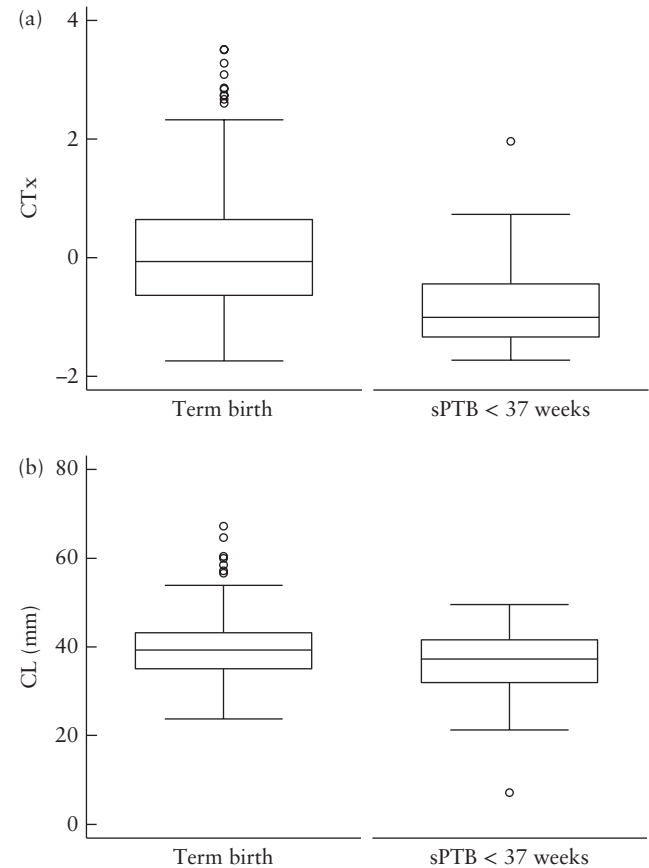
Box-and-whiskers plots of CTx-based score and CL in cases and controls are provided in Figure 3.

CL, CTx-based score and occurrence of sPTB in the six women with CL < 25 mm are shown in Table 2. CTx-based score in women with CL < 25 mm was significantly lower compared with women with CL ≥ 25 mm ( $-1.02$  vs  $-0.01$ ;  $P = 0.01$ ). CTx-based score was associated independently with sPTB after adjusting for confounders (history of sPTB, conization or Müllerian malformation, and CL < 25 mm): OR 0.31 (95% CI, 0.17–0.56;  $P < 0.001$ ) vs aOR 0.37 (95% CI, 0.19–0.64;  $P = 0.001$ ). CL < 25 mm was the only potential confounder that changed the estimate of risk by 10% or more.



**Figure 2** Flowchart of recruited women who had cervical texture assessed on ultrasound at 19 + 0 to 24 + 6 weeks' gestation. IOL, induction of labor; PPRM, preterm prelabor rupture of membranes; PTB, preterm birth; sPTB, spontaneous preterm birth.

The AUC for CTx-based score to predict sPTB < 37 + 0 weeks' gestation (0.77; 95% CI, 0.66–0.87) was higher than for CL (0.60; 95% CI, 0.47–0.72);  $P = 0.02$  (Figure 4). The optimal cut-off point for the CTx-based score based on the ROC curve was  $-0.68$ , with sensitivity of 70.4%, specificity 77.4%, LR+ 3.1 and



**Figure 3** Box-and-whiskers plots of cervical texture (CTx)-based score (a) and cervical length (CL) (b) in 27 women who delivered spontaneously < 37 weeks' gestation (sPTB) and in 283 women selected randomly who delivered at term.

**Table 1** Maternal and pregnancy characteristics of women assessed on ultrasound between 19 + 0 and 24 + 6 weeks' gestation for cervical length (CL) and cervical texture (CTx) who had spontaneous preterm birth (sPTB) < 37 weeks or term birth

Characteristic	Total cohort (n = 310)	sPTB (n = 27)	Term birth (n = 283)	P
Maternal age (years)	33 (28–37)	34 (29–38)	33 (28–37)	0.44
Caucasian	223 (71.9)	20 (74.1)	203 (71.3)	0.80
Smoker	46 (14.8)	3 (11.1)	43 (15.2)	0.57
BMI (kg/m <sup>2</sup> )	23.0 (21.0–26.1)	25.2 (20.3–26.6)	23.0 (21.0–26.1)	0.69
Nulliparous	159 (51.3)	10 (37.0)	149 (52.7)	0.08
Previous sPTB	35 (11.3)	6 (22.2)	29 (10.2)	0.03
Conization/Müllerian malformation	15 (4.8)	4 (14.8)	11 (3.9)	0.01
GA at scan (weeks)	21 (20.3–22.3)	21.2 (20.3–23.1)	20.6 (20.3–22.2)	0.53
CL at scan (mm)	38.6 (34.3–42.6)	37.7 (32.2–41.5)	38.6 (34.5–42.8)	0.26
CL < 25 mm	6 (1.9)	5 (18.5)	1 (0.4)	< 0.001
CTx-based score	-0.13 (-0.73–0.59)	-1.01 (-1.34 to 0.45)	-0.07 (-0.64 to 0.64)	< 0.001
GA at delivery (weeks)	39.4 (38.4–40.3)	34.6 (32.5–36)	39.6 (38.6–40.3)	NA
Birth weight (g)	3275 (2945–3530)	2300 (1600–2550)	3340 (2990–3560)	NA

Data given as median (interquartile range) or n (%). BMI, body mass index; CL, cervical length; CTx, cervical texture; GA, gestational age; NA, not applicable.

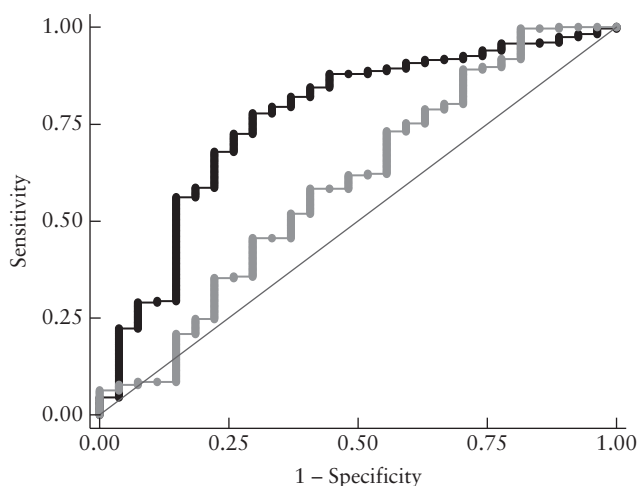
LR– 0.4 (Table 3). Conversely, for CL the cut-off was 35.5 mm with sensitivity of 44.4%, specificity 68.2%, LR+ 1.4 and LR– 0.8. Using CL < 25 mm as the cut-off, sensitivity was 14.8%, specificity 98.6%, LR+ 10.5 and LR– 0.9 (Table 3).

## DISCUSSION

This study provides evidence that findings on quantitative analysis of mid-trimester CTx are associated with sPTB < 37 + 0 weeks' gestation. The CTx-based score was significantly different between women delivering preterm and those delivering at term ( $P < 0.001$ ), independent of confounders. Although only one woman with short CL delivered at term, her CTx-based score was higher

**Table 2** Cervical length (CL), cervical texture (CTx)-based score and occurrence of spontaneous preterm birth (sPTB) < 37 weeks' gestation in six women with CL < 25 mm at 19 + 0 to 24 + 6 weeks' gestation

Case	CL (mm)	CTx-based score	sPTB
1	23.5	–1.06	Yes
2	23.2	–0.85	Yes
3	23.1	–1.34	Yes
4	21.3	–1.46	Yes
5	20.2	–0.07	No
6	7.1	–0.99	Yes



**Figure 4** Receiver–operating characteristics curves of CTx-based score (●—) and cervical length (—●) for prediction of sPTB < 37 + 0 weeks' gestation in 27 women.

**Table 3** Discriminative performance of cervical texture (CTx)-based score and cervical length (CL) assessed on ultrasound between 19 + 0 and 24 + 6 weeks' gestation for prediction of spontaneous preterm birth < 37 + 0 weeks' gestation

Predictor	Cut-off*	Sensitivity (n (%))	Specificity (n (%))	LR+ (95% CI)	LR– (95% CI)
CTx-based score	–0.68†	19/27 (70.4)	219/283 (77.4)	3.1 (2.2–4.3)	0.4 (0.2–0.7)
CL	35.5 mm†	12/27 (44.4)	193/283 (68.2)	1.4 (0.9–2.2)	0.8 (0.6–1.2)
CL	< 25 mm	4/27 (14.8)	279/283 (98.6)	10.5 (2.8–39.6)	0.9 (0.7–1.0)

\*Values below cut-off indicate increased risk. †Optimal cut-off based on receiver–operating characteristics curve. LR+, positive likelihood ratio; LR–, negative likelihood ratio.

compared with those of women with a short cervix who delivered preterm (–0.07 vs –1.06), supporting the finding that CTx is associated independently with sPTB, regardless of CL measurement. CTx-based score also showed a significantly larger AUC than did CL (0.77 vs 0.60,  $P = 0.03$ ).

The main strength of this study is that it addresses the association of a technologically innovative ultrasound tool (CTx) with a clinical event (sPTB) in a large cohort of mid-trimester women in the general population. This finding adds to that of a previous longitudinal study that demonstrated the feasibility of CTx for the quantification of cervical changes throughout normal pregnancy in a sample of 700 images obtained between 20 + 0 and 41 + 6 weeks' gestation<sup>13</sup>. Therefore, this method could be applied during the second and third trimesters of pregnancy to evaluate cervical remodeling and identify changes undetectable when using CL or on clinical examination. An additional strength is that the algorithm was tested using a model validation technique (LOOCV) to assess how the results could be generalized to an independent dataset and limit overfitting issues, thereby maximizing robustness.

We acknowledge a number of limitations. Firstly, offline CL measurements were used. In clinical practice, CL is measured online during the examination. We measured it offline intentionally because CL is, at present, not measured routinely in the general population in our center. The offline measurement was made simultaneously with ROI delineation for CTx analysis to ensure that all investigators and patients remained blinded to the results.

Another limitation is the low number of events of sPTB ( $n = 27$ ), allowing us to show only an association between the CTx-based score and sPTB. This low rate (4.9%) of sPTB is akin to that found in other European series<sup>17,18</sup>. The prevalence of history of sPTB (22.2% vs 10.2%) and cervical conization or the presence of a Müllerian anomaly (14.8% vs 3.9%) was significantly higher in cases than in controls. However, on removal of these candidate confounders from the model, the CTx-based score maintained its statistically significant association with sPTB.

A further limitation is that the robustness, in terms of using different ultrasound equipment, was not tested quantitatively for the cervix images. However, the robustness of the feature extraction method used and the statistical learning procedure has been shown in previous studies<sup>10,11,19</sup>. All ultrasound equipment used in this study has been tested for use in texture analysis and is currently used in clinical practice to assess fetal lung maturity.

It is worth mentioning that the features selected using the LBP method correspond to specific changes in speckle patterns that might be related to microstructural changes when the cervix is remodeled prematurely. In our work, a homogeneous region of the stroma was evaluated, assuming that acoustic properties of this region might change due to premature remodeling of the cervix. However, to provide insight or interpretation on the structural or histological changes beyond the changes observed in LBP is not possible at this point of the research.

Currently, there is evidence supporting that a mid-trimester short cervix (CL < 25 mm) increases the risk for sPTB<sup>20</sup>. Despite this, universal CL screening in the general population remains controversial. This is in part due to the low prevalence of cervical shortening and the current controversy on the consequences of this observation in terms of treatment<sup>21–24</sup>. However, its limited sensitivity is a major obstacle<sup>7,8,17,18,25</sup>. It is for this reason that there is a lot of ongoing research into evaluation of the cervix using other modalities, such as its distensibility and tissue stiffness<sup>26–31</sup>, and composition and optical characteristics<sup>32–39</sup>. These tools may contribute to an improved identification of women at risk for sPTB. To date, cervical elastography, which measures the percentage of tissue deformation when oscillatory compression is applied, has been the most studied method<sup>40–42</sup>. Low strain values in the internal cervical os are associated with a significantly lower risk of sPTB<sup>42</sup>. However, elastography has some important technical limitations<sup>41,43</sup>. The principal one is the inability to standardize the force applied for inducing tissue deformation<sup>44</sup>, whereas CTx analysis relies on images ‘at rest’ in a way that is similar to that for CL measurement. Ultrasonic attenuation has also been investigated for the identification of women at risk of sPTB, and results have suggested that low attenuation may be an additional early marker of sPTB<sup>45</sup>. To sum up, most of the developing ultrasound tools are based on the same hypothesis, i.e. that changes in cervical microstructure, and therefore in cervical properties, can be detected by different methods (e.g. acoustic attenuation<sup>46</sup>, shear wave elasticity<sup>39</sup> or texture analysis<sup>13</sup>).

In conclusion, sPTB is associated with mid-trimester CTx changes. We propose that larger validation studies with a new set of images are required to create a predictive model.

## ACKNOWLEDGMENTS

This publication has been funded with support of the Erasmus+ Programme of the European Union (Framework Agreement number: 2013-0040). This publication reflects the views only of the authors, and the Commission cannot be held responsible for any use that may be made of the information contained therein. Additionally, the research leading to these results has received partial funding from ‘la Caixa’ Foundation, Cerebra Foundation for the Brain Injured Child (Carmarthen, Wales, UK), AGAUR 2014 SGR grant number 928, and ‘la Secretaria

d’Universitats i Recerca del Departament d’Economia i Coneixement de la Generalitat de Catalunya’ (A.P.: 2014DI083).

## Disclosure

E.G., J.D. and M.P. have served as scientific advisers to Transmural Biotech.

## REFERENCES

1. Blencowe H, Cousens S, Chou D, Oestergaard M, Say L, Moller AB, Kinney M, Lawn J. Born too soon: the global epidemiology of 15 million preterm births. *Reprod Health* 2013; 10 Suppl 1: S2.
2. Blencowe H, Cousens S, Oestergaard MZ, Chou D, Moller AB, Narwal R, Adler A, Vera Garcia C, Rohde S, Say L, Lawn JE. National, regional, and worldwide estimates of preterm birth rates in the year 2010 with time trends since 1990 for selected countries: a systematic analysis and implications. *Lancet* 2012; 379: 2162–2172.
3. Liu L, Johnson HL, Cousens S, Perin J, Scott S, Lawn JE, Rudan I, Campbell H, Cibulskis R, Li M, Mathers C, Black RE. Global, regional, and national causes of child mortality: an updated systematic analysis for 2010 with time trends since 2000. *Lancet* 2012; 379: 2151–2161.
4. Chang HH, Larson J, Blencowe H, Spong CY, Howson CP, Cairns-Smith S, Lackritz EM, Lee SK, Mason E, Serazin AC, Walani S, Simpson JL, Lawn JE. Preventing preterm births: analysis of trends and potential reductions with interventions in 39 countries with very high human development index. *Lancet* 2013; 381: 223–234.
5. Romero R, Dey SK, Fisher SJ. Preterm labor: One syndrome, many causes. *Science* 2014; 345: 760–765.
6. Feltoch H, Hall TJ, Berghella V. Beyond cervical length: emerging technologies for assessing the pregnant cervix. *Am J Obstet Gynecol* 2012; 207: 345–354.
7. Orzechowski KM, Boelig RC, Baxter JK, Berghella V. A universal transvaginal cervical length screening program for preterm birth prevention. *Obstet Gynecol* 2014; 124: 520–525.
8. Son M, Grobman WA, Ayala NK, Miller ES. A universal mid-trimester transvaginal cervical length screening program and its associated reduced preterm birth rate. *Am J Obstet Gynecol* 2016; 214: 365.e1–365.e5.
9. Temming LA, Durst JK, Tuuli MG, Stout MJ, Dicke JM, Macones GA, Cahill AG. Universal cervical length screening: implementation and outcomes. *Am J Obstet Gynecol* 2016; 214: 523.e1–523.e8.
10. Bonet-Carne E, Palacio M, Cobo T, Perez-Moreno A, Lopez M, Piraquive JP, Ramirez JC, Botet F, Marques F, Gratacos E. Quantitative ultrasound texture analysis of fetal lungs to predict neonatal respiratory morbidity. *Ultrasound Obstet Gynecol* 2015; 45: 427–433.
11. Palacio M, Cobo T, Martínez-Terrón M, Rattá GA, Bonet-Carne E, Amat-Roldán I, Gratacos E. Performance of an automatic quantitative ultrasound analysis of the fetal lung to predict fetal lung maturity. *Am J Obstet Gynecol* 2012; 207: 504.e1–504.e5.
12. Tenorio V, Bonet-Carne E, Botet F, Marques F, Amat-Roldán I, Gratacos E. Correlation between a semiautomated method based on ultrasound texture analysis and standard ultrasound diagnosis using white matter damage in preterm neonates as a model. *J Ultrasound Med* 2011; 30: 1365–1377.
13. Baños N, Perez-Moreno A, Migliorelli F, Trigriner L, Cobo T, Bonet-Carne E, Gratacos E, Palacio M. Quantitative analysis of the cervical texture by ultrasound and correlation with gestational age. *Fetal Diagn Ther* 2017; 41: 265–272.
14. Kagan KO, Sonek J. How to measure cervical length. *Ultrasound Obstet Gynecol* 2015; 45: 358–362.
15. Ojala T, Pietikainen M, Mäenpää T. Multiresolution gray-scale and rotation invariant texture classification with local binary patterns. *IEEE Trans Pattern Anal Mach Intell* 2002; 24: 971–987.
16. Nanni L, Lumini A, Brahnam S. Local binary patterns variants as texture descriptors for medical image analysis. *Artif Intell Med* 2010; 49: 117–125.
17. Kuusela P, Jacobsson B, Söderlund M, Bejlum C, Almström E, Ladfors L, Hagberg H, Wennerholm UB. Transvaginal sonographic evaluation of cervical length in the second trimester of asymptomatic singleton pregnancies, and the risk of preterm delivery. *Acta Obstet Gynecol Scand* 2015; 94: 598–607.
18. van der Ven J, van Os MA, Kazemier BM, Kleinrouweler E, Verhoeven CJ, de Miranda E, van Wassenaer-Leemhuis AG, Kuiper PN, Porath M, Willekes C, Woiski MD, Sikkema MJ, Roumen FJ, Bossuyt PM, Haak MC, de Groot CJ, Mol BW, Pakrati E. The capacity of mid-pregnancy cervical length to predict preterm birth in low-risk women: a national cohort study. *Acta Obstet Gynecol Scand* 2015; 94: 1223–1234.
19. Palacio M, Bonet-Carne E, Cobo T, Perez-Moreno A, Sabriá J, Richter J, Kacerovsky M, Jacobsson B, García-Posada RA, Bugatto F, Santistevé R, Vives À, Parra-Cordero M, Hernandez-Andrade E, Bartha JL, Carretero-Lucena P, Tan KL, Cruz-Martínez R, Burke M, Vavilala S, Iruretagoyena I, Delgado JL, Schenone M, Vilanova J, Botet F, Yeo GS, Hyett J, Deprest J, Romero R, Gratacos E. Prediction of neonatal respiratory morbidity by quantitative ultrasound lung texture analysis: a multicenter study. *Am J Obstet Gynecol* 2017; 217: 196.e1–196.e14.
20. To MS, Skentou CA, Royston P, Yu CK, Nicolaidis KH. Prediction of patient-specific risk of early preterm delivery using maternal history and sonographic measurement of cervical length: a population-based prospective study. *Ultrasound Obstet Gynecol* 2006; 27: 362–367.

21. Goya M, Pratorcorona L, Merced C, Rodó C, Valle L, Romero A, Juan M, Rodríguez A, Muñoz B, Santacruz B, Bello-Muñoz JC, Llubra E, Higuera T, Cabero L, Carreras E. Cervical pessary in pregnant women with a short cervix (PECEP): an open-label randomised controlled trial. *Lancet* 2012; **379**: 1800–1806.
22. Nicolaides KH, Syngelaki A, Poon LC, Picciarelli G, Tul N, Zamprakou A, Skyfta E, Parra-Cordero M, Palma-Dias R, Rodriguez Calvo J. A randomized trial of a cervical pessary to prevent preterm singleton birth. *N Engl J Med* 2016; **374**: 1044–1052.
23. Norman JE, Marlow N, Messow CM, Shennan A, Bennett PR, Thornton S, Robson SC, McConnachie A, Petrou S, Sebire NJ, Lavender T, Whyte S, Norrie J. Vaginal progesterone prophylaxis for preterm birth (the OPPTIMUM study): a multicentre, randomised, double-blind trial. *Lancet* 2016; **387**: 2106–2116.
24. Romero R, Nicolaides KH, Conde-Agudelo A, O'Brien JM, Cetingoz E, Da Fonseca E, Creasy GW, Hassan SS. Vaginal progesterone decreases preterm birth  $\leq$  34 weeks of gestation in women with a singleton pregnancy and a short cervix: an updated meta-analysis including data from the OPPTIMUM study. *Ultrasound Obstet Gynecol* 2016; **48**: 308–317.
25. Miller ES, Tita AT, Grobman WA. Second-trimester cervical length screening among asymptomatic women: An evaluation of risk-based strategies. *Obstet Gynecol* 2015; **126**: 61–66.
26. Cabrol D, Jannet D, Le Houezec R, Dudzik W, Bonoris E, Cedard L. Mechanical properties of the pregnant human uterine cervix use of an instrument to measure the index of cervical distensibility. *Gynecol Obstet Invest* 1990; **29**: 32–36.
27. Hee L, Liao D, Sandager P, Gregersen H, Uldbjerg N. Cervical stiffness evaluated in vivo by endoflip in pregnant women. *PLoS One* 2014; **9**: e91121.
28. Bauer M, Mazza E, Jabareen M, Sultan L, Bajka M, Lang U, Zimmermann R, Holzapfel GA. Assessment of the in vivo biomechanical properties of the human uterine cervix in pregnancy using the aspiration test: a feasibility study. *Eur J Obstet Gynecol Reprod Biol* 2009; **144** Suppl 1: S77–S81.
29. Tekesin I, Hellmeyer L, Heller G, Römer A, Kühnert M, Schmidt S. Evaluation of quantitative ultrasound tissue characterization of the cervix and cervical length in the prediction of premature delivery for patients with spontaneous preterm labor. *Am J Obstet Gynecol* 2003; **189**: 532–539.
30. Peralta L, Mourier E, Richard C, Charpigny G, Larcher T, Ait-Belkacem D, Balla NK, Brasselet S, Tanter M, Muller M, Chavatte-Palmer P. In vivo evaluation of cervical stiffness evolution during induced ripening using shear wave elastography, histology and 2 photon excitation microscopy: insight from an animal model. *PLoS One* 2015; **10**: e0133377.
31. Badir S, Mazza E, Zimmermann R, Bajka M. Cervical softening occurs early in pregnancy: characterization of cervical stiffness in 100 healthy women using the aspiration technique. *Prenat Diagn* 2013; **33**: 737–741.
32. O'Connell MP, Avis NJ, Brown BH, Killick SR, Lindow SW. Electrical impedance measurements: an objective measure of prelabor cervical change. *J Matern Fetal Neonatal Med* 2003; **14**: 389–391.
33. Baños A, Wolf M, Grawe C, Stahel M, Haensse D, Fink D, Hornung R. Frequency domain near-infrared spectroscopy of the uterine cervix during cervical ripening. *Lasers Surg Med* 2007; **39**: 641–646.
34. Maul H, Olson G, Fittkow CT, Saade GR, Garfield RE. Cervical light-induced fluorescence in humans decreases throughout gestation and before delivery: Preliminary observations. *Am J Obstet Gynecol* 2003; **188**: 537–541.
35. Fittkow CT, Maul H, Olson G, Martin E, MacKay LB, Saade GR, Garfield RE. Light-induced fluorescence of the human cervix decreases after prostaglandin application for induction of labor at term. *Eur J Obstet Gynecol Reprod Biol* 2005; **123**: 62–66.
36. McFarlin BL, Bigelow TA, Laybed Y, O'Brien WD, Oelze ML, Abramowicz JS. Ultrasonic attenuation estimation of the pregnant cervix: a preliminary report. *Ultrasound Obstet Gynecol* 2010; **36**: 218–225.
37. Kuwata T, Matsubara S, Taniguchi N, Ohkuchi A, Ohkusa T, Suzuki M. A novel method for evaluating uterine cervical consistency using vaginal ultrasound gray-level histogram. *J Perinat Med* 2010; **38**: 491–494.
38. Afzali N, Mohajeri M, Malek A, Alamatian A. Cervical gland area: a new sonographic marker in predicting preterm delivery. *Arch Gynecol Obstet* 2012; **285**: 255–258.
39. Rosado-Mendez IM, Palmeri ML, Drehfal LC, Guerrero QW, Simmons H, Feltovich H, Hall TJ. Assessment of structural heterogeneity and viscosity in the cervix using shear wave elasticity imaging: initial results from a rhesus macaque model. *Ultrasound Med Biol* 2017; **43**: 790–803.
40. Hernandez-Andrade E, Romero R, Korzeniewski SJ, Ahn H, Auriolles-Garibay A, Garcia M, Schwartz AG, Yeo L, Chaiworapongsa T, Hassan SS. Evaluation of cervical stiffness during pregnancy using semiquantitative ultrasound elastography. *Ultrasound Obstet Gynecol* 2013; **41**: 152–161.
41. Molina FS, Gomez LF, Florido J, Padilla MC, Nicolaides KH. Quantification of cervical elastography: a reproducibility study. *Ultrasound Obstet Gynecol* 2012; **39**: 685–689.
42. Hernandez-Andrade E, Romero R, Korzeniewski SJ, Ahn H, Auriolles-Garibay A, Garcia M, Schwartz AG, Yeo L, Chaiworapongsa T, Hassan SS. Cervical strain determined by ultrasound elastography and its association with spontaneous preterm delivery. *J Perinat Med* 2014; **42**: 159–169.
43. Khalil MR, Thorsen P, Uldbjerg N. Cervical ultrasound elastography may hold potential to predict risk of preterm birth. *Dan Med J* 2013; **60**: A4570.
44. Fruscalzo A, Mazza E, Feltovich H, Schmitz R. Cervical elastography during pregnancy: a critical review of current approaches with a focus on controversies and limitations. *J Med Ultrason* 2016; **43**: 493–504.
45. McFarlin BL, Kumar V, Bigelow TA, Simpson DG, White-Traut RC, Abramowicz JS, O'Brien WD Jr. Beyond cervical length: A pilot study of ultrasonic attenuation for early detection of preterm birth risk. *Ultrasound Med Biol* 2015; **41**: 3023–3029.
46. McFarlin BL, Balash J, Kumar V, Bigelow TA, Pombar X, Abramowicz JS, O'Brien WD Jr. Development of an ultrasonic method to detect cervical remodeling in vivo in full-term pregnant women. *Ultrasound Med Biol* 2015; **41**: 2533–2539.